



## Human case of fasciolosis in Serbia treated with triclabendazole

### Humana fasciolozu u Srbiji lečena triklabendazolom

Milorad Pavlović<sup>\*†</sup>, Zorica Dakić<sup>‡</sup>, Branko Milošević<sup>\*†</sup>, Miloš Korać<sup>\*†</sup>,  
Branko Brmbolić<sup>\*†</sup>, Aleksandar Džamić<sup>§</sup>

<sup>\*</sup>Clinic for Infectious and Tropical Diseases, <sup>†</sup>Faculty of Medicine, University of Belgrade, Belgrade, Serbia; <sup>‡</sup>Parasitological Laboratory, Clinical Center of Serbia, Belgrade, Serbia; <sup>§</sup>Laboratory of Parasitology, Institute of Microbiology and Immunology, Faculty of Medicine, University of Belgrade, Belgrade, Serbia

#### Abstract

**Introduction.** The number of humans infected by *Fasciola hepatica* is increasing worldwide. Humans can become accidental hosts by ingesting drinking water or plants contaminated with *metacercariae*. **Case report.** We reported a case of a 68-year-old Serbian woman, in which the diagnosis of acute fasciolosis had been established after serious diagnostic concerns. Based on clinical picture (episodic right upper quadrant abdominal pain, febrility and generalized body pain) and biochemical analyses (high eosinophilia and high activity of alkaline phosphatase), she was appointed as suspected to the acute fasciolosis. Stool and duodenal aspirate exams were negative for *Fasciola ova*. In the absence of adequate serologic diagnostic for fasciolosis in Serbia, the diagnosis was confirmed using enzyme immunoassays and immunoblot at the Institute for Tropical Diseases in Hamburg, Germany. Soon after triclabendazole was administered, the symptoms disappeared and biochemical values returned to normal. **Conclusion.** The diagnosis of human fasciolosis may be problematic and delayed, especially in non-endemic areas, because physicians rarely encounter this disease and a long list of other diseases must be considered in the differential diagnosis. The syndrome of eosinophilia, fever, and right upper quadrant abdominal pain suggest acute fasciolosis. Unclear source does not rule out fasciolosis.

#### Key words:

fasciola hepatica; liver diseases, parasitic; humans; diagnosis; anthelmintics; treatment outcome.

#### Apstrakt

**Uvod.** Broj ljudi zaraženih parazitom *Fasciola hepatica* je u porastu širom sveta. Čovek postaje slučajni domaćin unošenjem infektivnih oblika, metacerkarija, kontaminiranom vodom ili biljkama. **Prikaz bolesnika.** U radu je prikazana 68-godišnja bolesnica iz Srbije, kod koje je nakon dijagnostičkog lutanja postavljena dijagnoza akutne fascioleze. Na osnovu kliničke slike (bol pod desnim rebarnim lukom, febrilnost, generalizovani bol), visoke eozinofilije i povišene aktivnosti alkalne fosfataze u serumu posumnjalo se na akutnu fasciolozu. U fecesu i duodenalnom aspiratu nisu nađena jaja *Fasciola hepatica*. U nedostatku imunološke dijagnostike za fasciolozu u Srbiji, dijagnoza je postavljena na osnovu prisustva specifičnih antitela imunoenzimskim testom i potvrđena imunoblot metodom u Institutu za tropske bolesti u Hamburgu, Nemačka. Lečenje je sprovedeno primenom triklabendazola, posle čega su se simptomi povukli, a biohemijske vrednosti vratile u normalu. **Zaključak.** Humana fasciolozu može biti teška za dijagnostiku naročito u neendemskim područjima, gde kliničari retko pomisle na nju i gde je duga lista bolesti koje treba isključiti u diferencijalnoj dijagnostici. Sindrom eozinofilije, febrilnost i bolovi ispod desnog rebarnog luka sugerišu akutnu fasciolozu. Nejasan izvor infekcije ne isključuje fasciolozu.

#### Ključne reči:

fasciola hepatica; jetra, parazitarne bolesti; ljudi; dijagnoza; antihelmintici; lečenje, ishod.

#### Introduction

Fasciolosis is a zoonotic infection caused by *Fasciola* (*F.*) *hepatica* and *gigantica*. Human fasciolosis (HF) is endemic in some parts of South America, Africa, Eastern Asia and Europe <sup>1,2</sup>. Cases of human infection by *F. hepatica* are not uncommon in European countries <sup>3</sup> and can be predominantly found in France, Portugal, Spain and the former

USSR <sup>1</sup>, where fasciolosis is highly endemic in domestic animals.

Humans can become accidental hosts of this parasite by ingesting contaminated drinking water or plants in endemic area. Infective *metacercariae* excyst in the duodenum and larvae penetrate the wall of the small intestine, the peritoneal cavity, the liver capsule, and pass through the liver tissue into the biliary tract. High prevalence of HF does not neces-

sarily occur in areas where fasciolosis is a major veterinary problem<sup>1,3</sup>. Animal fasciolosis is enzootic to some parts of former Yugoslavia, with no recent reports related to it. Survival of *F. hepatica* in this area is related to numerous animal hosts, the presence of *Lymnaea truncatula* snails as the original intermediate host, and also suitable environmental and climatic factors. Recent studies indicate that sheep and cattle are the main reservoir of *F. hepatica* in the territory of the former Yugoslavia<sup>4,5</sup>.

The last patient with fasciolosis was treated more than 20 years ago at the Clinic for Infectious and Tropical Diseases in Belgrade. Human fasciolosis is a disease whose incidence is difficult to determine in Serbia because it is not a subject to mandatory reporting, it was not described in our literature in the last several decades, there were no oral presentations at medical meetings, diagnostics market is not developed and there are no effective drugs. There are also no requirements for the procurement and registration of the specific drugs for fasciolosis, so we can conclude that it is rarely diagnosed and cured.

### Case report

A 68-year-old woman was admitted at the Clinic for Infectious and Tropical Diseases in Belgrade on March 10, 2005. The patient was a pensioner from Belgrade, who spent the last few months in a village near Trebinje in Herzegovina. Her last travel, out of borders of former Yugoslavia, was in Canada, two and a half years ago. She had a medical history of benign breast node which was surgically removed in 1984. The patient had been in a good health until the end of November 2004, when she developed episodic right upper quadrant (RUQ) abdominal pain which spread to the right shoulder, occasional bloating, fever (39–40°C), shaking chills, occasional dizziness, weakness and fatigue. This condition persisted and she was admitted at the Department of Hematology of Clinical Hospital Center “Zvezdara”, Belgrade (from January 10 to February 9, 2005) with suspicion to eosinophilic leukemia. Detailed clinical, laboratory and radiographic tests were performed. The laboratory tests revealed mild normocytic normochromic anemia, high eosinophilia, high serum activity of alkaline phosphatase (ALP), which maintained during all hospitalizations, with normal alanine aminotransferase (ALT) and aspartate aminotransferase (AST) levels. Abdominal ultrasound (US) showed the inhomogeneous right liver lobe. Computed tomography (CT) scan showed hypodense changes (total diameter up to 5 cm) in the right liver lobe below the diaphragm predominantly localized posteriorly and centrally that are partly flown together. After application of contrast most of the changes remained hypodense and only edges were imbibed by getting a grape look appearance. The left liver lobe was homogeneous. Two enlarged lymph nodes (up to 2 cm in size) were evident in the retroperitoneum.

The diagnosis of malignancy was initially suspected and for additional examination she was transferred to the Department of Surgery (from February 9 to February 14, 2005). Because the diagnosis of malignancy was initially considered, laparoscopic liver biopsy under visual control was per-

formed at the Department of surgery on February 14, 2005, and before obtaining the histological diagnosis the patient was released. Two fragments of the liver tissue were obtained by biopsy. The first specimen showed less liver tissue and largely fibrous tissue infiltrated by lymphocytes and numerous eosinophils. The second specimen showed liver tissue with fibrosis and small cells infiltration of the portal fields. Some portal areas had a strong, almost serious proliferation of connective tissue with bile ducts and blood vessels. One part of the specimen showed nodules with strong fibrosis and septa that form pseudo-tubules similar to inactive cirrhosis. There was also a fibrous tissue containing bile ducts and numerous blood vessels with thickened walls. There were no signs of malignancy. A conclusion was that it was focal nodular hyperplasia. After receiving a histopathological finding the patient was advised to continue testing at the Clinic for Infectious and Tropical Diseases because of her subjective complaints, fever and eosinophilia, the existence of non-specific histopathological lesions in the liver and the history of travelling to tropical areas in the past.

Upon admission to our Clinic, her temperature was 37.8°C. Abdominal exam showed localized tenderness over RUQ and a palpable liver border on the right costal margin. The rest of the physical exam was unremarkable. On admission, hemoglobin level was 118 g/L, erythrocyte count was  $3.96 \times 10^{12}/L$ , the white-cell count was  $13.5 \times 10^9/L$  with 43.7% eosinophils, the platelet count was  $243 \times 10^9/L$ . The erythrocyte sedimentation rate (ESR) was 60/90 mm/h and serum biochemical analysis revealed the following values: Fe 7.1 µmol/L, ALP 174 U/L; ALT 16 U/L; AST 14 U/L and alpha amylase 49 U/L. Total bilirubin was 7 µmol/L, fibrinogen value was 5.6 g/L, C-reactive protein (CRP) 10 mg/L. Antibodies to *Brucella* spp, HCV, HBV were not found. The results of tumor markers (CEA, CA 19.9, AFP) were within normal range. Laboratory was controlled weekly (AST 20 U/L, ALT 26 U/L, than AST 57 U/L, ALT 68 U/L). The highest value for CRP was 15 mg/L, and fibrinogen 6.6 g/L.

In view of the persistent fever, hepatomegaly, and eosinophilia serologic tests for a variety of parasites were requested. Serology was negative for *Toxoplasma gondii*, *Trichinella spiralis*, *Echinococcus*, *Leishmania*, *Entamoeba histolytica*, *Schistosoma*, but *Toxocara (T.) canis* (1.27) and *Cysticercus* (1.21) enzyme immunoassays (EIA) were mildly positive.

Chest radiographs showed no abnormalities. Abdominal US on March 16 showed homogeneous liver of normal size, with no visible focal changes. Two enlarged periportal hilar lymph nodes (diameter 18 mm and 17 mm) with hypoechoic appearance were detected.

The liver-spleen scintiscan on March 21, 2005, showed mild hepatomegaly with track-like zones of hypofixation of radiofarmaci (RF, radioactive colloids) in the right posterior liver lobe. Liver and spleen scintigraphy showed the enlarged liver, with straight upper edges. The contours of the upper part of the right hepatic lobe were irregular and uneven. The distribution of RF was non-homogeneous with the appearance of zones of weaker binding of RF. Track-like zones of hypofixation of RF in the right posterior liver lobe were observed resembling two oval recesses of the top of the right lobe.

It was unclear whether these changes were focal zones or there was an extrahepatic origin of these recesses. The spleen was mildly enlarged with tiny, oval discrete zones of lower levels binding of RF. Because ultrasound did not show focal liver lesions, radiologist recommended further investigation (CT and scintigraphic control).

Abdominal CT (on April 4, 2005) demonstrated multiple hypodense foci with subcapsular location on both sides of the liver, partially merged (Figure 1). Repeated US on April 11, 2005 showed irregular oval hyperechoic solitary liver lesion, in the upper right lobe of the liver, near the confluence of the right hepatic vein, 52 × 42 mm in size, without a hypoechoic halo (Figure 2).

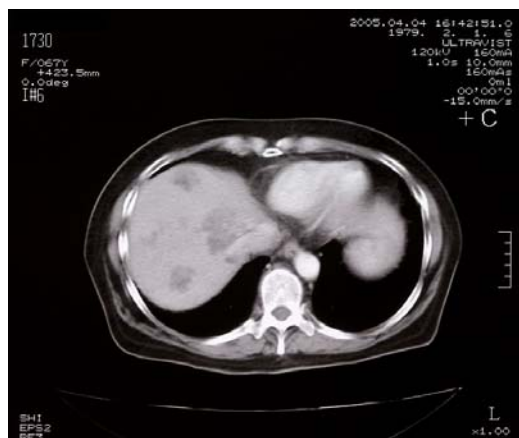

Fig. 1 – Abdominal computed tomography (CT) scan shows multiple hypodense foci with subcapsular location.

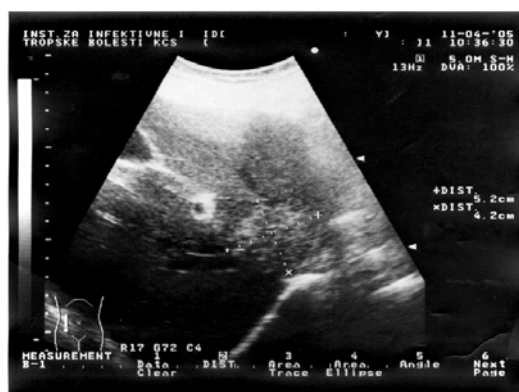


Fig. 2 – Irregular oval hyperechoic solitary liver lesion (52 × 42 mm in size), in the upper part of the right liver lobe.

A detailed re-evaluation with repeated investigation of liver biopsy (April 23, 2005) revealed a histopathological picture suggesting parasitic infection. In a small part of the obtained material were hepatocytes, and in the rest of the sample there was young granulation tissue infiltrated by eosinophils and other inflammatory cells. Portal fields were normal in size, easy to moderately infiltrated, mainly by eosinophils, with a small number of other inflammatory cells. Glycogenated nuclei were seen in the parenchyma. Inflammatory cells of the same type as those found in portal fields were seen in the sinusoids.

Repeated stool and duodenal aspirate examinations were negative for *Fasciola* eggs. Since the serology for *T. canis* was not affirmative, along with the fact that *Toxocara* generally gives changes in central nervous system and eyes, this type of affection of the liver and bile ducts with high eosinophilia resembled acute fasciolosis. Because acute fasciolosis was highly suggested and serological diagnosis for fasciola was not available in Serbia, the patient's serum was sent to the Institute for Tropical Diseases in Hamburg, Germany. Serology to *Wuchereria bancrofti*, *Schistosoma mansoni*, *Dirofilaria immitis* and *Strongyloides stercoralis* was negative but the EIA was positive for *Fasciola*-specific IgG antibodies. The final diagnosis of fasciolosis was confirmed by immunoblot testing.

After the diagnosis was confirmed, triclabendazole (Egaten<sup>®</sup>, Novartis) was administered at the dose of 10 mg/kg for 1 day.

Control abdominal ultrasound on May 4, 2005, was unchanged. Before the patient was discharged on May 5, 2005, ESR was 52/84 mm/h, leukocytes  $10.4 \times 10^9/L$  with eosinophilia 34%, platelets  $227 \times 10^9/L$ , AST 15 U/L, ALT 17 U/L, ALP 125 U/L.

The patient appeared clinically well two weeks after the treatment. At a 6 month follow-up examination, her eosinophil count, hematological and biochemical results were normal (ESR 15 mm/hour, CRP 6 mg/L, leukocytes  $7.2 \times 10^9/L$ , eosinophilia 12%).

## Discussion

We reported a case of acute HF of uncertain origin of infection. Although the beginning of the disease coincides with the patient's several months stay in Herzegovina, considering the fact that there were no reports of animal fasciolosis in this area, we could not be sure if the infection was positively acquired there. A source of infection was unclear, too. It could be due to the consumption of improperly washed fresh vegetables since the patient used to buy them supplied in the green market with no defined product sourcing or she could have been infected by chewing grass contaminated with *metacercaria* or by contaminated water. This is consistent with data about human infection in areas where people do not have a history of eating watercress<sup>2</sup>. The experimental results suggest that humans who consume raw dishes prepared from fresh livers infected with immature flukes could become infected with *F. hepatica*<sup>6</sup>, but our patient did not have these data in her history. It fits into the explanation of Mas-Coma et al.<sup>1</sup> about the existence of isolated autochthonous, nonconstant cases<sup>7</sup>.

Infection with *F. hepatica* has a variable clinical presentation depending on the stage of the disease. The syndrome of eosinophilia, fever, and right abdominal upper quadrant pain, without jaundice, hypodense liver lesions on CT, and an appropriate exposure history (history of eating fresh vegetables that may be improperly washed) suggests acute fasciolosis. A negative history does not rule out fasciolosis. High ESR, anaemia and leukocytosis with high eosinophilia (may be up to 70%) are frequent findings in infected individuals in the early phase of the disease<sup>2</sup>. Clearly, febrile diseases and other para-

sitic infections causing eosinophilia and/or similar symptoms should be ruled out. Hypereosinophilic syndrome was rarely diagnosed as *Toxocara*, *Strongyliodes* and *Fasciola*<sup>8</sup>. In this case, the clinical presentation and liver problem indicate that HF was probably the unique diagnosis. Because of the endemicity of toxocarosis and cysticercosis in Serbia, positive serology for both infections was probably due to anamnestic antibody response or a nonspecific antibody response. Aminotransferase levels are usually in normal range or are only minimally elevated, and bilirubin levels are typically in normal range, as was the case with our patient. Saba et al.<sup>9</sup> reported 28 patients with acute fasciolosis who predominantly had epigastric pain, fatigue, fever and RUQ abdominal pain and elevated eosinophilia, ALT level and acute-phase reactant in laboratory findings. Eosinophilia in fasciolosis is striking and almost always present<sup>9,10</sup>. According to results of Haseeb et al.<sup>11</sup> high activity of ALP, as well as significantly high eosinophilia and low hemoglobin, are the most significant laboratory features of HF, as it was in our case.

Hepatic lesions are produced by migration of juvenile *Fasciola* through liver in the invasive stage. Histologically, they correspond to microabscesses and tunnel-like areas of parenchymal necrosis<sup>12</sup>. Characteristic parenchymal lesions are clearly demonstrated by imaging procedures. Imaging techniques used for diagnosis of fasciolosis include radiology, radioisotope scanning, US, CT scan or MRI that may show the tunnels caused by the migrating young flukes or the flukes in the biliary passages (chronic infection)<sup>7</sup>. The first abdominal CT finding in our patient showing hypodense clustered lesions in a periphery of the right lobe of the liver and enlarged retroperitoneal lymph nodes was compatible with hepatic phase of fasciolosis.

Han et al.<sup>13</sup> reported the characteristic radiological features in 5 patients with hepatic fasciolosis that involve cluster of microabscesses arranged in track-like hypodense lesions with subcapsular location, and a very slow evolution of the lesion. Marcos et al.<sup>14</sup> further reported hepatomegaly as a common finding on abdominal CT scan in patients with fasciolosis. First abdominal CT finding in our patient was compatible with hepatic phase of fasciolosis, but radiologists were not familiar with findings of this disease. Typical findings on US, which should be absolutely performed as initial assessment procedure, facilitate the diagnosis.

Magnetic resonance imaging (MRI) reflects the extent of the lesions better than CT in the earlier stage. In the late parenchymal phase, the extent of the lesions on the specimens is well correlated with both CT scan and MRI<sup>15</sup>. Perportal lymph node enlargement or lymphadenopathy is helpful in the diagnosis<sup>16</sup>, which was the case in our patient.

The biliary phase is usually asymptomatic, and only intermittent cholangitis may be the prominent sign, but it is rarely reported that it can lead to extrahepatic obstruction and cholestasis<sup>17</sup>.

The diagnosis of fasciolosis is complex and requires application of both direct and indirect methods of diagnostics. Diagnosis of *F. hepatica* infection has traditionally relied on detecting the presence of eggs in fecal samples or bile specimens, but this method is unreliable and complicated.

Negative stool examinations do not rule out fasciolosis. A period of at least 3 to 4 months is necessary for *F. hepatica* flukes to attain sexual maturity in humans<sup>18</sup>. Our patient was admitted to our Clinic with a 3-month history of illness. This can be the reason why the stool examination was negative. Human is generally believed to be a non-suitable host and the possibility of hepatic infections by flukes which are unable to attain maturity, cannot be disregarded<sup>19</sup>.

At present, the routine diagnosis of HF is based on the detection of anti-fluke antibodies in the serum. Specific antibodies to *Fasciola* may be detectable within 2 to 4 weeks after infection, which is 5 to 7 weeks before eggs appear in stool. Immunological techniques present the advantages of being applicable during all phases of the disease, but especially during the acute phase. This is important in areas where HF is rare<sup>1</sup>, such as in Serbia. Although, early diagnosis of fasciolosis is performed mainly on serum assay<sup>10</sup>, for rare parasitic infection, such as fasciolosis, there is a lack of registered diagnostic tests in Serbia. The current test of choice for immunodiagnosis of human *F. hepatica* infection is EIA<sup>20</sup> combined with confirmation of positives by immunoblot<sup>14</sup> with a sensitivity of 100% and a specificity of 97.8%<sup>21</sup>. Since signs and symptoms of fasciolosis may be confused with a wide variety of disorders, including hepatobiliary and extrahepatobiliary diseases (hepatitis, cholecystitis, cholangitis, liver abscess, brucellosis, leishmaniasis, schistosomiasis and primary and secondary hepatobiliary malignancies)<sup>16</sup>, diagnosis and treatment are often problematic and delayed, which was the case in our patient.

Many drugs have been used to treat fasciolosis with variable success<sup>14,22-24</sup>. The first-line treatment of HF is with a single oral dose (10 mg/kg) of triclabendazole which is highly effective against mature and immature flukes, safe, and easy to use<sup>2,14,25</sup>. Treatment should be repeated when a single dose fails to cure the infection<sup>10</sup>. A single dose of triclabendazole was successful and without side effects in our patient. Albendazole, widely used in animal fasciolosis, is ineffective against human infections<sup>22</sup>, as it was the case in the presented patient.

## Conclusion

Human fasciolosis can be very difficult to diagnose, because it sometimes appears with atypical and severe clinical presentation. Problematic and delayed diagnosing is especially risky in nonendemic areas where clinicians are not familiar with this disease. The syndrome of eosinophilia, fever, and RUQ abdominal pain without jaundice; liver damage, which is manifested by a high activity of liver enzymes and hypodense liver lesions on CT, including an appropriate exposure history, suggest acute fasciolosis. Unclear history does not rule out fasciolosis. Fortunately, with the exact diagnosis simple therapy with triclabendazole is extremely effective.

## Acknowledgments

This paper was presented in part at the 8th European Congress on Tropical Medicine and International Health (Copenhagen, Denmark, September 10–13, 2013).

## R E F E R E N C E S

1. Mas-Coma S, Bargues MD, Valero MA. Fasciolosis and other plantborne trematode zoonoses. *Int J Parasitol* 2005; 35(11–12): 1255–78.
2. Soliman MFM. Epidemiological review of human and animal fasciolosis in Egypt. *J Infect Developing Countries* 2008; 2(3): 182–9.
3. Arjona R, Riancho JA, Aguado JM, Salesa R, González-Macías J. Fasciolosis in developed countries: a review of classic and aberrant forms of the disease. *Medicine* 1995; 74(1): 13–23.
4. Rajkovic-Janje R, Bosnic S, Kosier N, Husnjak M. Invasion with endoparasites in sheep, goats and bovine cattle and its significance. *Praxis Veterinaria* 2000; 48(1–2): 41–5 (Croatian)
5. Milanovic V, Nitovski A, Kulisic Z, Mirilovic M. *Fasciola hepatica* findings in cattle of Jablanica region (Serbia) *Veterinarski glasnik* 2007; 61(1–2): 89–97. (Serbian)
6. Taira N, Yoshifuji H, Boray JC. Zoonotic potential of infection with *Fasciola* spp. by consumption of freshly prepared raw liver containing immature flukes. *Int J Parasitol* 1997; 27(7): 775–9.
7. Esteban JG, Bargues MD. Epidemiology of human fasciolosis: a review and proposed new classification. *Bull WHO* 1999; (77): 340–6.
8. Ehrhardt S, Burchard GD. Eosinophilia in returning travelers and migrants. *Dtsch Arztebl Int* 2008; 105(46): 801–7.
9. Saba R, Korkmaz M, Inan D, Mamikoglu L, Turhan O, Gunseren F et al. Human fasciolosis. *Clin Microbiol Infect* 2004; (10): 385–7.
10. Dauchy FA, Vincendeau P, Lifermann F. Eight cases of fasciolosis: clinical and microbiological features. *Med Mal Infect* 2006; 36(1): 42–6.
11. Haseeb AN, El-Shazly AM, Arafat MA, Morsy AT. Clinical, laboratory and ultrasonography features of proven human fasciolosis. *J Egypt Soc Parasitol* 2003; 33(2): 397–412.
12. Pagola Serrano MA, Vega A, Ortega E, Gonzales A. Computed tomography of hepatic fasciolosis. *J Comput Assist Tomog* 1987; 11(2):269–72.
13. Han JK, Choi BI, Jae Min Cho, Chung KB, Han MC, Kim CW. Radiological findings of human fasciolosis. *Abdom Imaging* 1993; 18(3): 261–4.
14. Marcos LA, Tagle M, Terashima A, Bussalieu A, Ramirez C, Carrasco C, et al. Natural history, clinicoradiologic correlates, and response to triclabendazole in acute massive fasciolosis. *Am J Trop Med Hyg* 2008; 78(2): 222–7.
15. Taberi MS, Aminzade Z, Shokobi Sh, Birang Sh, Agbaze K. Case Report. Hepatobiliary fasciolosis: clinical and radiological features. *Iranian J Parasitol* 2007; 2(4): 48–55.
16. Kabaalioglu A, Ceken K, Alimoglu E, Saba R, Cubuk M, Arslan G, et al. Hepatobiliary fasciolosis: sonographic and CT findings in 87 patients during the initial phase and long-term follow-up. *AJR Am J Roentgenol* 2007; 189(4): 824–8.
17. Moghadami M, Mardani M. Fasciola hepatica: A cause of obstructive jaundice in an elderly man from Iran. *Saudi J Gastroenterology* 2008; 14(4): 208–10.
18. Espino AM, Díaz A, Pérez A, Finlay CM. Dynamics of antigenemia and coproantigens during a human *Fasciola hepatica* outbreak. *J Clin Microbiol* 1998; 36(9): 2723–6.
19. Acosta-Ferreira W, Vercelli-Retta J, Falconi LM. Fasciola hepatica human infection. Histopathological study of sixteen cases. *Virchows Arch A Path Anat Histol* 1979; 383(3): 319–27.
20. Hernandez RJ, Blasco CA, Valdivieso BMF, Arribas MMI, Paciencia AM, Rodríguez SE, et al. Familial outbreaks of fasciolosis: usefulness of serologic investigation by enzyme immunoassay. *Rev Clin Esp* 1998; (198): 33–5.
21. Mansour WA, Kaddab MA, Sjafer ZA, al Assal FM, Derbala MF. A monoclonal antibody diagnoses active *fasciola* infection in humans. *J Egypt Soc Parasitol* 1998; 28(3): 711–27.
22. World Health Organization. WHO/CDS/NTD/PCT/2007.1. Report of the WHO Informal Meeting on use of triclabendazole in fasciolosis control. WHO headquarters, Geneva, Switzerland: World Health Organization; 2006.
23. Rossignol JF, Abaza H, Friedman H. Successful treatment of human fasciolosis with nitazoxanide. *Trans R Soc Trop Med Hyg* 1998; 92(1): 103–4.
24. Hien TT, Truong NT, Minh NH, Dat HD, Dung NT, Hue NT, et al. A randomized controlled pilot study of artesunate versus triclabendazole for human fasciolosis in central Vietnam. *Am J Trop Med Hyg* 2008; 78(3): 388–92.
25. Keiser J, Engels D, Buscher G, Utzinger J. Triclabendazole for the treatment of fasciolosis and paragonimiasis. *Expert Opin Investig Drugs* 2005; 14(12): 1513–26.

Received on April 3, 2012.

Revised on November 21, 2012.

Accepted on December 3, 2012.